


PATIENT

Sophie Walsh

PRESENTING CLINICAL SIGNS

 History: Grade 1-2 systolic heart murmur. Assess prior to dental. No current medications.
 -Abnormal PE/Chem/CBC/UA Results: Bloodwork WNL.

SPECIES

Canine

ECHOCARDIOGRAM FINDINGS

2D, m-mode, color flow and doppler imaging is available. Mild mitral valve leaflet thickening with no obvious prolapse into the left atrial lumen. Trace mitral regurgitation is identified. Normal left atrial dimension. Normal LV diameter with normal myocardial function. The tricuspid valve appears subjectively normal. No TR. The right heart is normal. No overt evidence of pulmonary arterial hypertension. The pulmonic and aortic valves are normal in morphology and mobility. No aortic abnormalities identified, with normal outflow velocity. Normal pulmonic outflow velocities. No aortic insufficiency. No pulmonic insufficiency. No pericardial or pleural effusion noted. No cardiac tumors observed.

BREED

Beagle

SEX

Female Spayed

CARDIAC CHART
AGE

11 years

WEIGHT

22.2lbs

INTERPRETED BY

 Maggie Machen Lamy,
 DVM DACVIM
 (Cardiology)

IMAGING PERFORMED BY

Crystal Hill, RVT

HOSPITAL NAME

 Tansley Woods
 Veterinary Hospital

REFERRING VET

Dr. Petrowski

INVOICE

24360

DATE

5/24/22

CANINE CARDIAC PARAMETERS	MR VMAX (m/s)	TR VMAX (m/s)	LA/AO (Boon method)	LA/AO (Heart Base; Swe)	FS (%)	EF (%)	EPSS (cm)
NORMAL PARAMETER	4.5-5.5	<2.7	1.3	<1.6	28-40	40-100	<0.6
PATIENT	NM	NA	1.0	1.1	34	60	0.3
CANINE CARDIAC PARAMETERS	HR (BPM)	AV VMAX (m/s)	PV MAX (m/s)	BODY WEIGHT (kg)	LA 2D short axis Base view (cm)	LVIDd Avg; 2D and m-mode short axis (cm)	LVIDs Avg; 2D and m-mode short axis (cm)
NORMAL PARAMETER	50-100	0.7-1.7	0.7-1.6	BELOW	BELOW	BELOW	BELOW
PATIENT	107	1.6	1.4	10.1	1.4	2.9	1.9
*Normal chamber parameters expressed as a mean value (SD)				3	1.27 (5.3)	2.46 (2.46)	1.36 (5.5)
BODY WEIGHT DEPENDENT PARAMETERS				5	1.40 (4.5)	2.74 (5.2)	1.60 (4.7)
<i>*Note: All measurements based upon multi-modal images and methods. An average value is reported.</i>				10	1.50 (3.8)	3.27 (3.5)	2.06 (3.1)
				15	1.83 (2.0)	3.71 (2.4)	2.43 (2.1)
				20	2.02 (1.9)	4.14 (2.2)	2.80 (2.0)
				25	2.18 (2.4)	4.48 (2.9)	3.10 (2.5)
				30	2.33 (3.3)	4.83 (3.9)	3.39 (3.4)
				35	2.48 (4.3)	5.17 (5.0)	3.69 (4.5)
				40	2.62 (5.2)	5.48 (6.1)	3.96 (5.4)
				50	2.88 (7.1)	6.07 (8.3)	4.46 (7.4)

INTERPRETATION OF THE FINDINGS & FURTHER RECOMMENDATIONS

Overtly normal cardiac structure and function with no cause of a murmur identified. A small mitral leak is noted, which is unlikely to be heard on exam. Follow up for progression is advised. No other significant valvular insufficiencies were noted, and no structural issues identified. In the absence of significant volume changes (dehydration) or anemia, other possibilities include a physiologic flow murmur only present with elevated heart rates, or a small flow abnormality not seen here. It is reasonable to monitor periodically via recheck echocardiography in the future, particularly should the murmur persist/progress.



PATIENT

Sophie Walsh

No cardiac medications are indicated at this time. Monitor for any development of cough, labored breathing or exercise intolerance.

SPECIES

Canine

No cardiac contraindication for general anesthesia.

BREED

Beagle

Recommend recheck echocardiogram in 12-18 months to screen for progression or development of concurrent cardiac disease that the preexisting murmur may mask.

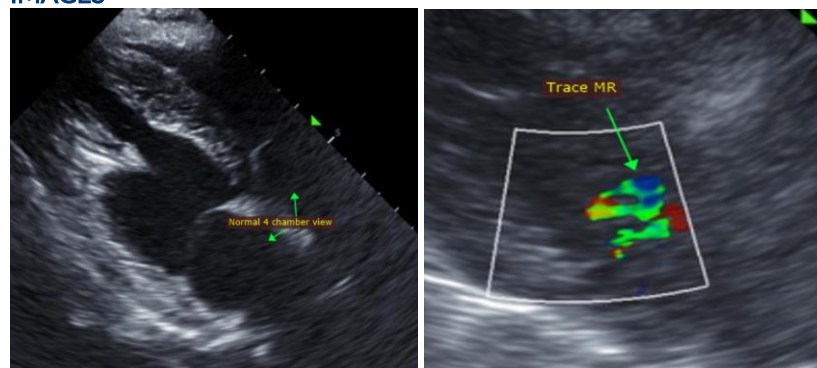
SEX

Female Spayed

AGE

11 years

IMAGES



WEIGHT

22.2lbs

The information and recommendations provided are based on the images presented by the referring veterinarian. No evaluation can be communicated regarding pathology that was not visible in the image/video clips provided.

INTERPRETED BY

Maggie Machen Lamy,
DVM DACVIM
(Cardiology)

Thank you for this referral. This report was generated using transcription software, and minor dictation errors may be present. If the clinical or image interpretation does not parallel your findings or if I can be of any further assistance, please contact me.

Maggie Machen Lamy, DVM

Diplomate of the American College of Veterinary Internal Medicine (Cardiology)

info@sonopath.com

IMAGING PERFORMED BY

Crystal Hill, RVT

HOSPITAL NAME

Tansley Woods
Veterinary Hospital

REFERRING VET

Dr. Petrowski

INVOICE

24360

DATE

5/24/22